




# Progesterone Levels and Vaginal Cytology in Relation to Canine Ovulation Timing

**TARGET**  
CANINE OVULATION TIMING  
*the test veterinarians trust*  
1-800-999-1961

## A Early Proestrus

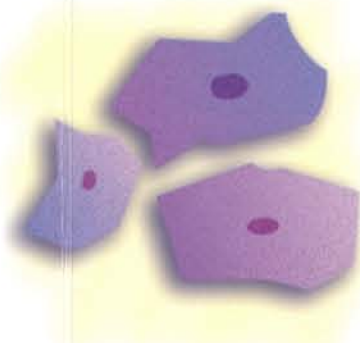
Composed of parabasal cells, small and large intermediate cells; a few superficial cells.



A

## B Late Proestrus


Predominantly superficial cells and medium to large intermediate cells. The edges are straight and the cells are flattened.



B

## C Estrus

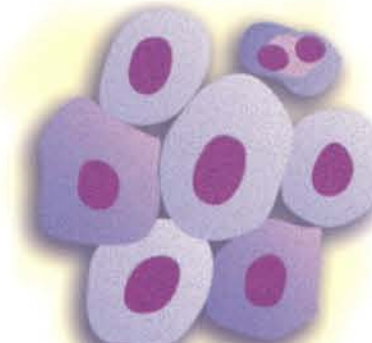
The cells are fully cornified.



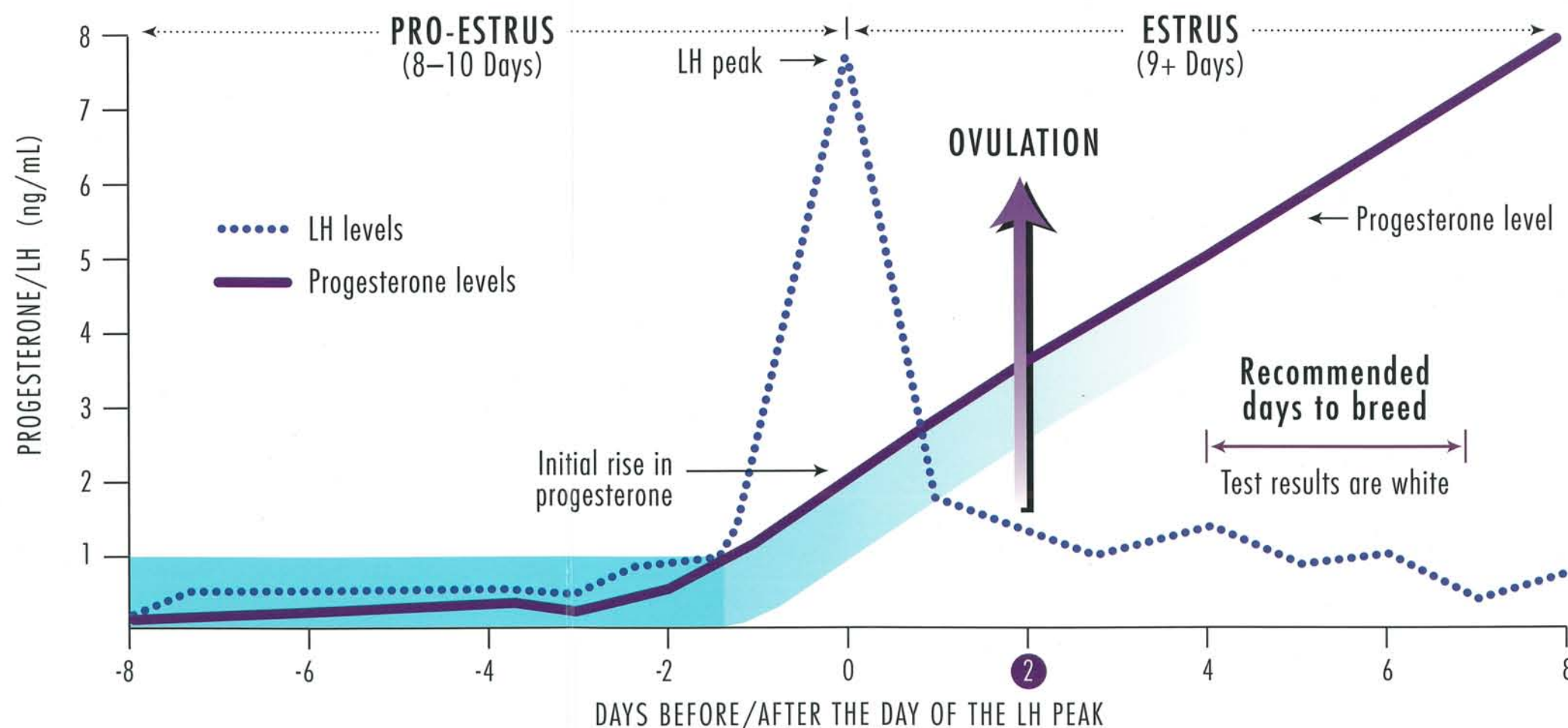
C

## D Diestrus

Onset of diestrus is characterized by the sudden appearance of parabasal cells; a change from predominantly cornified to predominantly noncornified.



D



Day 0: Day of LH peak and first rise of progesterone

Day 2: Ovulation

Bright blue is the test result for LOW progesterone levels | Light blue is the test result for INTERMEDIATE progesterone | White is the test result for HIGH progesterone

# Types of Cells



### Parabasal Cells

Round or oval, large nucleus.



### Small Intermediate Cells

Slightly larger than parabasal cells, borders irregular.



### Large Intermediate Cells

Large cells with irregular borders.



### Superficial Cells

Largest cell seen; borders irregular, no nucleus present (fully cornified cells).



### Metestrus Cells

Parabasal cells with infiltration of a varying number of nucleated cells.